

The role of medical thoracoscopic lung biopsy in diagnosis of diffuse parenchymal lung diseases

Magdy M. Omar^a, Ahmad S. Alhalafawy^b, Nashwa M. Emara^c,
Mohammad A.E. El-Mahdy^a, Etemad Abdelsalam^a

Background Interstitial lung disease in the immunocompetent patient is often a difficult challenge for the clinician, especially when no diagnostic clues are present. A clear diagnosis confirmed by biopsy allows clinicians and patients to discuss fully the implications of the disease.

Aim The aim was to evaluate the role of medical thoracoscopic lung biopsy in diagnosis of patients with diffuse parenchymal lung diseases.

Patients and methods The study included 15 patients with diffuse parenchymal lung diseases of unknown etiology. They had undergone full history taking, complete clinical examination, ventilatory function tests (spirometry), arterial blood gases analysis, high-resolution computed tomography chest, coagulation profile, platelet count, collagen profile, and thoracoscopic lung biopsy by medical thoracoscopy for histopathologic examination. Follow-up of the patients in the inpatient unit was done by chest radiography and clinical evaluation.

Results The pathological diagnosis of cases was six (40%) patients with extrinsic allergic alveolitis, five (33.3%) patients with malignancy, three patients with idiopathic interstitial pneumonias, one (6.7%) patient with tuberculosis, and one (6.7%) patient with sarcoidosis. Regarding complications, one (6.7%) patient had pneumothorax after intercostal tube (ICT) removal, and three (20%) patients had subcutaneous emphysema. The duration of the ICT drainage was 3.1 ± 2.6

days. There was no wound infection, no bleeding, no persistent air leak after more than 24 h (Hs) from ICT insertion, no respiratory failure requiring ICU admission, and no mortality in the study sample.

Conclusion Thoracoscopic lung biopsy by medical thoracoscopy is useful in diagnosis of cases with diffuse parenchymal lung diseases of unknown etiology when lung biopsy is needed for accurate diagnosis. The procedure is safe. The procedure carries some complications that are not life threatening and can be minimized by good selection of patients.

Egypt J Bronchol 2019 13:155–161

© 2019 Egyptian Journal of Bronchology

Egyptian Journal of Bronchology 2019 13:155–161

Keywords: diffuse parenchymal lung disease, lung biopsy, medical thoracoscopy

^aDepartment of Chest Diseases, ^bFaculty of Medicine, Banha University, Banha, ^cDepartment of Chest Diseases, Faculty of Medicine, Cairo University, Cairo, Egypt

Correspondence to Etemad Abdelsalam, MBBCH, MSC, MD chest, Lecturer of Chest Diseases and Tuberculosis, Chest Department, Banha University, Banha, 13511, Egypt. Tel: +20 122 888 2651; e-mail: etemadabdelsalam2@gmail.com

Received 1 July 2018 **Accepted** 23 November 2018

Introduction

Interstitial lung disease in the immunocompetent patient is often a difficult challenge for the clinician, especially when no diagnostic clues are present after a thorough clinical assessment, laboratory examination including serology for specific connective tissue disease, chest radiography, and high-resolution computed tomography (HRCT). Bronchoalveolar lavage and transbronchial biopsy are usually the next step [1]. Thoracoscopy has been safely and successfully performed by well-trained pulmonologists for several decades [2]. The introduction of modern video equipment and more refined instrumentation has expanded the indications [3]. Medical thoracoscopic lung biopsy (MTLB) in the diagnosis of interstitial lung disease can be considered a second choice after failure of bronchoalveolar lavage (BAL) and trans bronchial lung biopsy (TBLB) to provide the diagnosis, and this technique has some advantages over surgical lung biopsy (SLB). The possibility to take several biopsies under visual guidance and lower morbidity are the most important advantages [4].

Medical thoracoscopy is expected to progress and develop rapidly with future advances in the technology. With respect to its importance as a diagnostic, therapeutic, and research tool, it should be implemented as an essential part of all respiratory medicine training programs [5].

Aim

The aim of this work was to evaluate the role of MTLB in diagnosis of patients with diffuse parenchymal lung diseases.

Patients and methods

This is a prospective analytical study that included 15 patients with diffuse parenchymal lung diseases on

This is an open access journal, and articles are distributed under the terms of the Creative Commons Attribution-NonCommercial-ShareAlike 4.0 License, which allows others to remix, tweak, and build upon the work non-commercially, as long as appropriate credit is given and the new creations are licensed under the identical terms.

HRCT chest of unconfirmed diagnosis. The study was approved by the local institute ethics committee. All patients were subjected to thorough history taking and clinical examination, HRCT chest, coagulation profile (prothrombin concentration) and platelet count, ventilatory function tests (spirometry), arterial blood gases, collagen profile [rheumatoid factor (RF) and antinuclear antibody (ANA), Cytoplasmic anti-neutrophil cytoplasmic antibodies (cANCA) and perinuclear anti-neutrophil cytoplasmic antibodies (pANCA)], and antineutrophil cytoplasmic antibodies (ANCA) c and p. Thoracoscopic lung biopsy was done by medical thoracoscopy under local anesthesia. The biopsy specimens were preserved in formalin-containing cups and sent for histopathological examination. The collected data were tabulated and analyzed.

Results

In the present study, there were three (20%) male patients and 12 (80%) female patients. Their mean age was 47 ± 12.2 years and ranged from 28 to 70 years. In the studied group, only two (13.3%) patients were smokers and 13 (86.7%) patients were nonsmokers. Dyspnea was the commonest symptom and was present in 100% of cases. Cough also was present in all cases but in 80% was productive and in 20% it was dry. Loss of weight was present in 20% of cases. Fever was present in 13.3% of cases, and hemoptysis was present in 6.7% of cases. In this study, the mean and SD values of oxygen saturation before thoracoscopy on room air was 92.5 ± 1.9 and the range was 91–96%. Moreover, the mean and SD values for oxygen saturation during thoracoscopy was 88.9 ± 2.1 , and the range was 87–92%. The O₂ saturation of the patients before the biopsy was 91% (minimal saturation) and 96% as maximum saturation. During the thoracoscopy procedure, while opening the chest wall allowing air to enter the pleural cavity without supplemental oxygen, it showed a minimum saturation of 87% and maximum saturation of 92%. Supplemental oxygen was administered to compensate for the drop in the saturation, and there was insignificant correlation between oxygen saturation before and oxygen saturation during thoracoscopy after induction of pneumothorax at 5% level of significance. In this study, the duration needed for intercostal tube (ICT) removal was variable, with minimum duration of 2 days and maximum duration of 6 days, and this was noted only in patients who developed surgical emphysema. There is a statistically significant difference between patients with and without complication regarding ICT drainage

duration, at 5% level of significance. There was insignificant negative correlation between forced vital capacity (FVC) and duration of ICT drainage at 5% level of significance.

Discussion

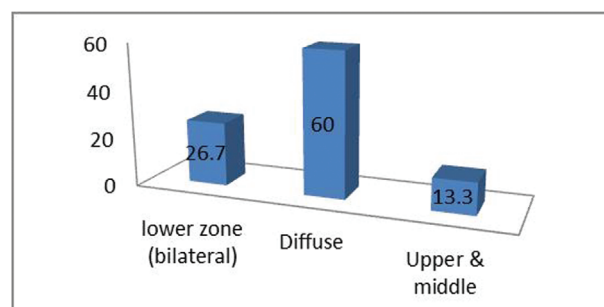
In the current study, pulmonary infiltrates were bilateral in all cases in the present study (Table 1, Fig. 1). This agrees with a study done by Elhadidy *et al.* [6]. and Elbadrawy *et al.* [7]. They reported that pulmonary infiltrates were bilateral and diffuse in all cases (100%). However, in a study done by Danes *et al.* [8], pulmonary infiltrate was bilateral in 51% of cases and localized in 49% of cases. In a study by Jain *et al.* [9], lung infiltrates were diffuse in 50% of cases and localized in 32.6% of cases, and 13.6% of cases presented with multiple lung nodules in the chest radiographs. In the present study (Table 2, Fig. 2), HRCT findings among the studied group were as

Table 1 Chest radiography findings: radiological distribution of abnormality in the radiography of studied cases of DPLD (the most affected areas)

Chest radiography findings	n (%)
Lower zone	4 (26.7)
Diffuse	9 (60)
Upper and middle zone	2 (13.3)

DPLD, diffuse parenchymal lung diseases.

Figure 1



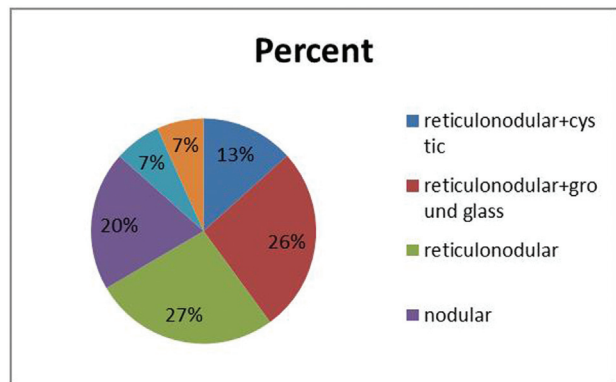
Chest radiography findings (radiological distribution of abnormality in the radiography) of studied cases.

Table 2 High-resolution computed tomography pattern in the study sample

HRCT pattern	n (%)
Reticulonodular-cystic	2 (13.3)
Reticulonodular+ground glass	4 (26.6)
Reticulonodular	4 (26.6)
Reticular	1 (6.7)
Nodular	3 (20%)
Consolidation (patchy)	1 (6.7%)

HRCT, high-resolution computed tomography.

Figure 2



High-resolution computed tomography pattern.

Table 3 Ventilatory function values among the studied group

	Mean±SD	Range %
FVC%	58.8±12.1	39–72%
FEV ₁ %	69.5±8.9	67–79%
FEV ₁ /FVC%	95.7±4.02	88–103%

FEV₁, forced expiratory volume in first second; FVC, forced vital capacity.

follows: the commonest presentation of the studied cases was as follows: reticulonodular infiltrate and reticulonodular with ground glass [ground glass opacity (GGO)] in 26.6% each, nodular infiltrate in 20% of patients, reticulonodular infiltrate in 13.3% of patients, and patchy (consolidation) reticular infiltrate in 6.7% of cases. In a study done by Elhadidy *et al.* [6], the commonest HRCT finding was reticulonodular infiltrate with GGO in 38.8% of cases, followed by consolidation in 22.2% of cases. In a study by Xaubet *et al.* [10], reticular opacities were found in 87.2% and ground glass opacities were found in 12.8%. In a study done by Elbadrawy *et al.* [7], nodular opacities were the most common CT chest findings, and they were present in 36.7%, followed by ground glass opacities in 23.3% followed by miliary shadow in 6.7% of cases, and honey combing was the least CT finding, and it was present in 3.3% of cases. The cause of the difference in the radiological finding between the result of this study and other studies is owing to different etiologies of the included cases. Table 3 shows that the forced expiratory volume in first second/FVC ratio was normal in all patients, and there is decrease in both FVC% and forced expiratory volume in first second % but the decrease in FVC% was marked, so all cases were diagnosed as restrictive lung disease. This agrees with a study done by Erbes *et al.* [11], who reported restrictive pulmonary function was present in 100% of patients (99 out of 99), and this is different from a study done by Elhadidy *et al.* [6], who found restrictive pulmonary function in 77.2%

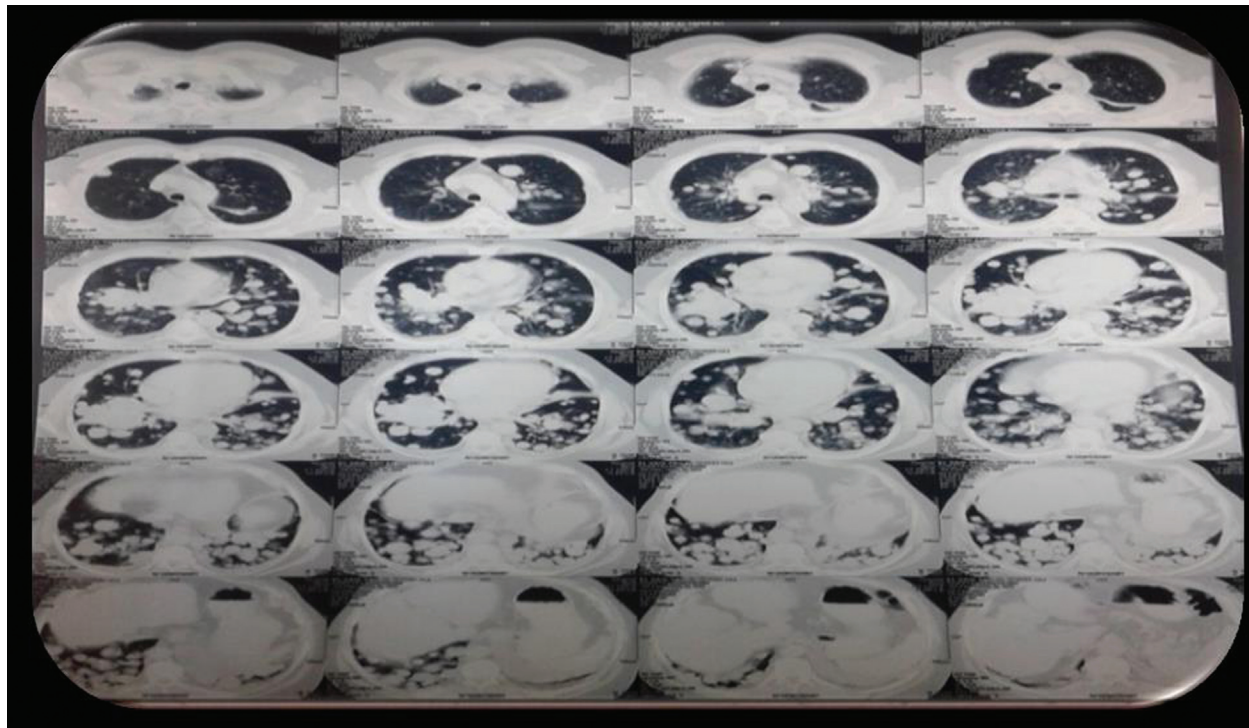
Table 4 Groups of final diagnosis obtained by VAMT lung biopsy

Diagnosis	n (%)
Extrinsic allergic alveolitis	6 (40)
Sarcoidosis	1 (6.7)
Tuberculosis	1 (6.7)
IIPS	2 (13.3)
UIP	1 (6.7)
NSIP	1 (6.7)
Malignancy	5 (33.3)
BAC	1 (6.7)
Mucoepidermoid carcinoma	1 (6.7)
Adenocarcinoma	3 (20)

BAC, bronchoalveolar carcinoma; IIPS, idiopathic interstitial pneumonias; NSIP, nonspecific interstitial pneumonia; UIP, usual interstitial pneumonia.

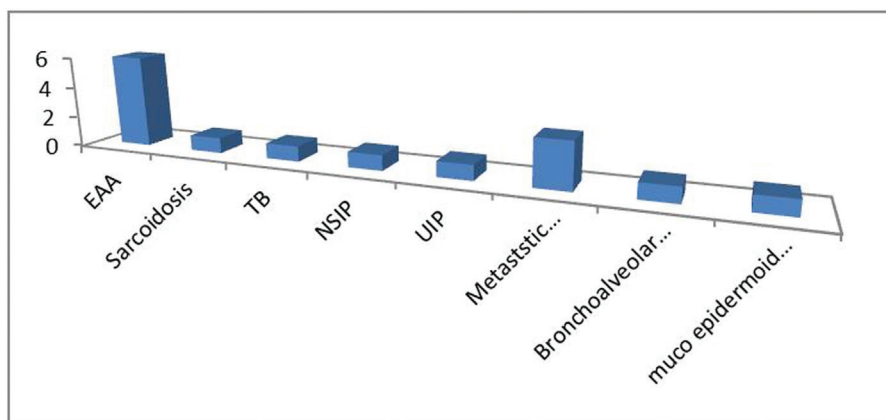
of patients and mixed function, obstructive and restrictive, in 27.8% of patients. Yang and Raghu [12] reported mixed patterns in the patients without coexisting emphysema may suggest sarcoid, hypersensitivity pneumonitis (HP), respiratory bronchiolitis associated interstitial lung disease (RB-ILD), lymphangioleiomyomatosis (LAM), and interstitial lung diseases (ILD) associated with asthma (chronic eosinophilic pneumonia). In the current study (Table 4, Figs 3–6), the diagnosis of cases was six patient with extrinsic allergic alveolitis with occupational history of bird breeding, five patients with malignancy, three patients with idiopathic interstitial pneumonias, one patient with tuberculosis, and one patient with sarcoidosis. Regarding patients diagnosed with malignancy, one patient was diagnosed as having mucoepidermoid carcinoma, one patient was diagnosed as having bronchoalveolar carcinoma, and three patients were diagnosed as having metastatic adenocarcinoma. Regarding the patients diagnosed as having idiopathic interstitial pneumonias, their types were one patient had usual interstitial pneumonia and another patient had nonspecific interstitial pneumonia (NSIP). In a study done by Elhadidy *et al.* [6], the commonest diagnosis in the studied patients was usual interstitial pneumonia pattern (38.9%), followed by adenocarcinoma (22.2%), NSIP (11.1%), and BOOP, silicosis, lymphoma, RB-ILD, and TB (5.6% each). In a study done by Morell *et al.* [13], the final diagnoses were IPF (16.8%), NSIP (3.8%), other IIP (19%), sarcoidosis (18.6%), HP (15%), malignancy (10.8%), PLCH (2.6%), and miscellaneous (11%). In a study done by Jain *et al.* [9], the final diagnoses were IPF (38.6%), NSIP (1.7%), other IIP (15.2%), sarcoidosis (14.9%), HP (6.6%), malignancy (3.3%), PLCH (2.9%), and miscellaneous (7.9%). In a study done by Agostini *et al.* [14], the final diagnoses were IPF (37.6%),

Figure 3



High-resolution computed tomography chest showed diffuse bilateral diffuse nodular lung infiltrations.

Figure 4

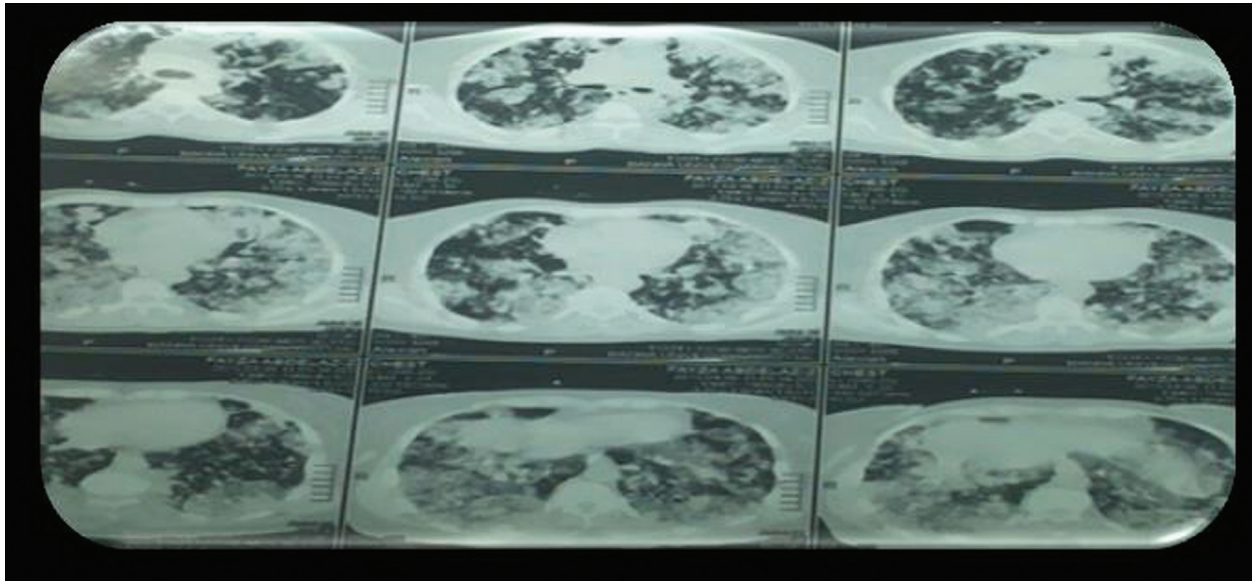


Final diagnosis among the studied group.

NSIP (5%), sarcoidosis (29.2%), HP (3.7%), malignancy (1.7%), PLCH (6.6%), and miscellaneous (14.9%). The difference between the results of this study and the other studies are owing to larger number of cases included in these studies. The overall diagnostic yield in this study was 100% (15/15 cases). This agrees with Boutin *et al.* [15] (100%). In their study, MTLB was done for 20 patients with ILDS, and up to eight biopsies were taken for each patients, and diagnostic yield was 100%. Rodgers *et al.* [16] reported diagnostic yield of 98%, which is slightly higher than Vansteenkiste *et al.* [4] (96.7%), Dijkman *et al.* [17] (90%), Vansteenkiste *et al.* [4] (75%) (in their

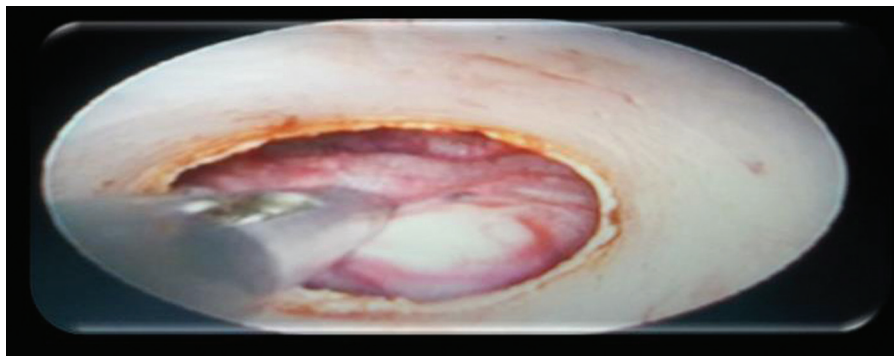
study, 24 patients with ILD were studied, and diagnosis could be made in 18 cases with a diagnostic yield of 75%), Elnady *et al.* [18] (87%), and Kapsenberg [19] (94%). In the current study (Table 5), there was no air leak after more than 24 h following the biopsy. This result disagrees with Nitin [20] who encountered air leak in 26% of cases (eight cases out of 30), although he was assessing the efficacy and safety of lung biopsy using medical thoracoscopy for diagnosis of diffuse interstitial infiltrates. Moreover, this result disagrees with Vansteenkiste *et al.* [4] who encountered air leak in 29% of cases (seven cases out of 24). In the study by Boutin *et al.*

Figure 5



Computed tomography of chest with contrast revealed diffuse bilateral patchy infiltrations.

Figure 6



The biopsy forceps grasping the lung while taking the biopsy.

Table 5 Complications in the study sample

Complications	n (%)
Subcutaneous emphysema	3 (20)
Air leak for more than 24 h after the procedure	0 (0)
Bleeding	0 (0)
Infection	0 (0)
ICU admission	0 (0)
Pneumothorax after ICT removal	1 (6.7)

ICT, intercostal tube.

[15], incidence of air leak was 15% (three cases out of 20 cases). Moreover, the result also disagrees with Elhadidy *et al.* [6] who encountered air leak for about 7 days in one case out of 18, approximately 5.6% of cases. Moreover, Elnady *et al.* [18] found that air leak occurred in 20% of patients (two cases out of 10); in the first patient, air leak persisted for 7 days, and in the second one, it persisted for 5 days. Pain occurred in all patients, and it was mild to moderate

and was controlled by NSAID medications. This agrees with Elhadidy *et al.* [6] who found pain in all cases, whereas Elnady *et al.* [18] found pain in six patients. It was mild to moderate and was controlled by NSAID medications. Pain was not found in cases done under general anesthesia. Approximately 6.7% of patients (one case out of 15) had pneumothorax after removal of the ICT. This pneumothorax resolved by supplementary high-flow oxygen and needed ICT insertion and resolved within 5 days. This incidence of postprocedure pneumothorax (pneumothorax after removal of the ICT tube) is lesser than the result encountered by Boutin *et al.* [15] which was 10.6% (eight cases out of 75). This result disagrees with Elnady *et al.* [18] who founded that 20% of patients (two cases out of 10) had pneumothorax after removal of the ICT; this pneumothorax resolved by supplementary high-flow oxygen without the need for reinsertion of another

Figure 7



Post-thoracoscopy chest radiography with subcutaneous emphysema.

ICT. No significant bleeding had occurred. This result agrees with Elnady *et al.* [18] who founded that bleeding was negligible (occurred in only one patient and it was about 20 ml). This result disagrees with Elhadidy *et al.* [6] who reported minor bleeding in 50% of patients. No infection occurred in the patients after insertion of the ICT. This result disagrees with Xaubet *et al.* [10] who recorded one (5.6%) case of empyema after ICT insertion. No patients needed ICU admission and there was no short-term mortality (30 days postprocedure) in the study group. Absence of mortality cases in this study is in agreement with the results obtained by Vansteenkiste and colleagues [4,15,6,21], where there were no mortality cases in these series. Three (20%) patients had surgical emphysema (Fig. 7) as a complication to the procedure, which had resolved completely by high-flow oxygen. Elhadidy *et al.* [6] reported surgical emphysema in 27.3% of patients (five out of 18). These results in general agree with Vansteenkiste *et al.* [4] who did not find major complications such as important bleeding or persistent bronchopleural fistula requiring thoracotomy, nor temporary respiratory insufficiency requiring mechanical ventilation, but low-grade fever was noted in three patients (3/24=12.5%) and minor bleeding in one (1/24=4.1%). Prolonged air leak (i.e. >7 days) was present in seven patients (7/24=29%).

Conclusion

The present study demonstrates the safety of lung biopsy by medical thoracoscopy in cases with diffuse parenchymal lung disease. The present study demonstrates the usefulness of MTLB in the diagnosis of cases with diffuse parenchymal lung disease of unknown etiology. The process of thoracoscopic lung biopsy by medical thoracoscopy carries some complications which are minor,

tolerable, and not life threatening in general. The present study demonstrates that thoracoscopic lung biopsy by medical thoracoscopy is a feasible and applicable process.

Recommendation

MTLB is a safe and useful method that should be used in the diagnosis of cases with diffuse parenchymal lung diseases of unknown etiology instead of video assisted thoracoscopic surgery (VATS) and surgical lung biopsy. Further studies should be performed on a larger number of diffuse lung diseases. Future studies are also needed to study the role of MTLB in the diagnosis of peripheral lung lesions, the comparison between MTLB by using electrocautery and MTLB by using cryocoagulation as regarding safety and usefulness in diagnosis of diffuse lung diseases, and the comparison between MTLB and lung biopsy by VATS regarding safety usefulness and cost in diagnosis of diffuse lung diseases.

Acknowledgements

The manuscript has been read and approved by all the authors. The requirements for authorship as stated earlier in this document have been met, and each author believes that the manuscript represents honest work.

Financial support and sponsorship

Nil.

Conflicts of interest

There are no conflicts of interest.

References

- 1 Raghun G. Interstitial lung disease diagnostic approach. Are CT scan and lung biopsy indicated in every patient. *AM J Respir Crit Care Med* 1995; 151:909–991.
- 2 Viskum K, Enk B. Complications of thoracoscopy. *Poumon Coeur* 1981; 37:25–28.

- 3 Mathur P, Astoul P, Boutin C. Medical thoracoscopy. Technical details. *Clin Chest Med* 1995; **16**:479–486.
- 4 Vansteenkiste J, Verbeke E, Thomeer M, Van Haecke P, Eeckhout AV, Demedts M. Medical thoracoscopic lung biopsy in interstitial lung disease: a prospective study of biopsy quality. *Eur Respir J* 1999; **14**:585–590.
- 5 Shoukri A. Medical thoracoscopy: past, present, and future. *Egypt J Bronchol* 2013; **7**:50.
- 6 Elhadidy T, Ibrahim M, Moustafa F, Elmaksoud A. Video assisted medical thoracoscopic lung biopsy in diagnosis of diffuse pulmonary infiltrate. *Egypt J Chest Dis Tuberc* 2016; **66**:PA2493.
- 7 Elbadrawy MF, Fathy AM, Amin MM, Abodda MA, Alsaid AR. Transbronchial lung biopsy and bronchoalveolar lavage in diagnosis of diffuse pulmonary infiltrates. *Egypt J Chest Dis Tubercul* 2006; **56**:66–72.
- 8 Danes C, Gonzalez JM, Pumarola T, Rano A, Benito N, Puig J. Pulmonary infiltrates in immunocompromised patients. *Am Soc Immunol* 2002; **40**:2134–2140.
- 9 Jain P, Sandur S, Meli Y, Arroliga AC, Stoller JK, Mehta AC. Role of flexible bronchoscopy in immune compromised patients with lung infiltrates. *Chest* 2004; **125**:712–722.
- 10 Xaubet A, Anocha J, Morell F, Rodriguez-Arias JM, Villena V, Blanquer R, *et al.* Report on the incidence of interstitial lung disease in Spain. *Sarcoidosis Vasc Diffuse Lung Dis* 1998; **21**:64–70.
- 11 Erbes R, Schaberg T, Loddenkamper R. Lung function tests in patients with pulmonary fibrosis: Are they useful for predicting outcome. *Chest* 1997; **111**:51–57.
- 12 Yang S, Raghu G. Clinical evaluation. In: Costabel U, duBois RM, Egan MM, editors. *Diffuse parenchymal lung disease*. Basel (Switzerland): Karger; 2007. 22–28.
- 13 Morell F, Reyes L, Domench G, Gracia J, Majo J, Ferrer J. Diagnosis and diagnostic procedures in 500 consecutive patients with clinical suspicion of interstitial lung diseases. *Arch Bronchoneumol* 2008; **44**:185–191.
- 14 Agostini C, Albero C, Barifi F, Harari S, Lusuardi M. First report of the Italian register for diffuse infiltrative lung disorders. *Mondali Arch Chest Dis* 2001; **56**:364–368.
- 15 Boutin C, Viallat J, Cargnino P, Rey F. Thoracoscopic lung biopsy. Experimental and clinical preliminary study. *Chest* 1982; **82**:44–48.
- 16 Rodgers B, Moazam F, Talbert J. Thoracoscopy: early diagnosis of interstitial pneumonitis in the immunologically suppressed child. *Chest* 1979; **75**:126–130.
- 17 Dijkman J, van der Meer J, Bakker W, Wever A, van der Broek P. Transpleural lung biopsy by the thoracoscopic route in patients with diffuse interstitial pulmonary disease. *Chest* 1982; **82**:76–83.
- 18 Elnady M, Shalaby A, Mohammad A. Evaluation of safety and feasibility and usefulness of thoracoscopic lung biopsy by medical thoracoscopy in diffuse lung infiltrates. *Chest* 2012; 435a 435b.
- 19 Kapsenberg P. Thoracoscopic biopsy under visual control. *Poumon Coeur* 1981; **37**:313–316.
- 20 Nitin A. *Evaluation of lung biopsy techniques for diagnosis of diffuse interstitial infiltrates*. ERS Annual Conference 2006; 740. E-Poster.
- 21 Brandt H. Biopsiepulmonare sous controle de la vue. *Poumon Coeur* 1981; **37**:301–313.